

ARTICLES

AVIAN BLOOD PARASITES - A REQUEST FOR AFRICAN MATERIAL

Roy A. Earlé and Gordon F. Bennett

Birds, like all other vertebrates, are hosts to myriads of parasites, including a number of species of single-celled Protozoa which inhabit the blood stream. Some of these parasites live within the red or the white cells and certain species can cause extreme mortality in populations of their hosts. This is particularly true of domestic birds such as chickens, turkeys and ducks but their impact on wild populations is poorly known. These blood parasites, collectively known as avian haematozoa (Figs. 1-6), are represented by species of the genera *Haemoproteus*, *Leucocytozoon*, *Plasmodium*, *Trypanosoma*, microfilaria and *Hepatozoon*, in that order of frequency of occurrence, with species of *Plasmodium*, *Trypanosoma*, microfilaria and *Hepatozoon* relatively infrequently encountered (probably in less than 5% of the sample). Most species of *Haemoproteus* are believed to be relatively benign in their impact on avian populations, but some species of both *Leucocytozoon* and *Plasmodium* are noted for their lethal impact on some species of birds. Species of *Haemoproteus* are transmitted from bird to bird through the agency of biting midges of the family Ceratopogonidae while species of *Leucocytozoon* are transmitted by ornithophilic (bird-loving) species of blackflies (Family Simuliidae) and *Plasmodium* is transmitted through the bites of a number of species of mosquitoes (Family Culicidae). The various species of these genera of haematozoa are host family (not host species) specific, and each avian family can be the host of one or more species of each parasite group.

South Africa is well known for its rich and diverse avifauna. Indeed, the Ethiopian Life Zone (that part of the African continent south of the Sahara) has the second greatest number of avian species in the world, second only to the bird fauna of South America. During the northern winter months, migrants from Europe and Asia swell the total number of species and sub-Saharan Africa has the greatest avian biomass of any life zone at this time.

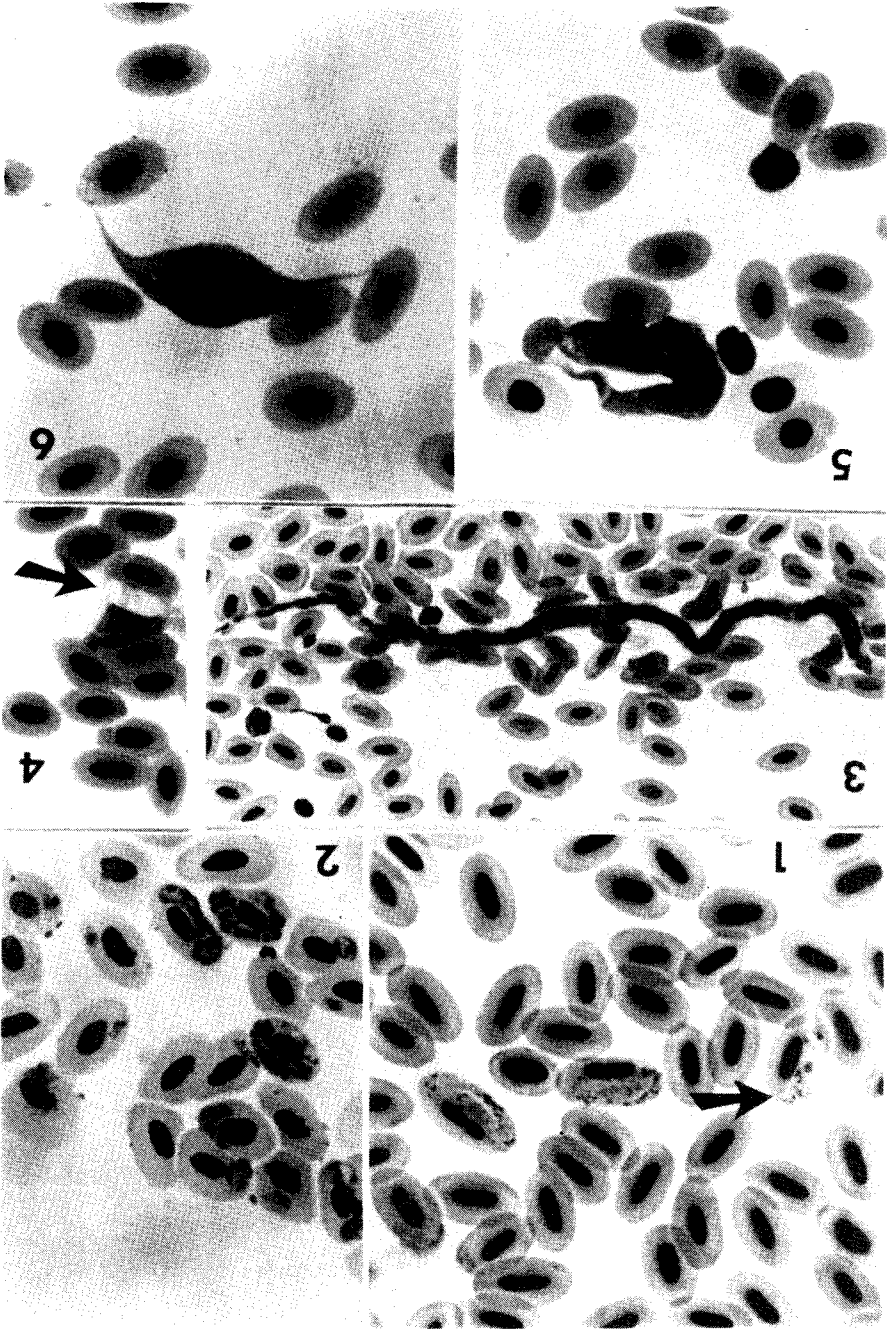
The diversity of the sub-Saharan avifauna is reflected in the large number of species of avian haematozoa that have been described from them. For example, there are over 60 species of *Haemoproteus* and 25 species of *Leucocytozoon* described from sub-Saharan birds and even the widely-distributed species of the genus *Plasmodium* are represented in Africa by 14 or more species. With further sampling of the African avifauna, this total may well increase dramatically. However, the descriptions of avian blood parasites from Africa were

frequently based on a single record and the host species has never been examined again. Among the haemoproteids, *Haemoproteus stellaris* was described from two individual Grey-rumped Swallows *Pseudhirundo griseopyga* and this host species has not been subsequently examined. Similarly, the Pygmy Kingfisher, *Ispidina picta*, is the host of the unique *Haemoproteus enucleator* which has been recorded from Ethiopia to Uganda, but not yet recorded in South Africa although the bird is relatively quite common. *Leucocytozoon beaurepairei* was described from a single Secretary Bird *Sagittarius serpentarius* and only four additional birds (all parasite-free) have been examined since that time. *Leucocytozoon dinizi* was described from a single Grey Lourie in 1947 in Mozambique and the parasite has not been recorded since. Most species of avian trypanosomes and filarioid worms described from African birds follow the same pattern. To check the validity of these records, the data base must be expanded. This expansion would be most easily accomplished if ringers, who handle both large numbers and a wide diversity of avian species, would take blood samples for analysis.

Although sub-Saharan Africa has an enormous diversity and numbers of avian species, less than 15 000 individuals have been examined for blood parasites in Africa since 1905 (Bennett, Earlé, Du Toit, Cassidy & Huchzermeyer, 1991). This total does not compare favourably with the over 50 000 examinations recorded in each of North and South America in the same time interval (Greiner, Bennett, White & Coombs 1975; White, Greiner, Bennett & Herman 1978; Woodworth-Lyons, Caines and Bennett 1989) or the nearly 60 000 examined by McClure, Poonswad, Greiner & Laird (1978) over a 10-year period in Southeast Asia. Yet, in a recent issue of Safring News (19: 29), there is a report that over 41 000 birds were ringed in the 1988-89 ringing season, a figure nearly three times the total birds examined for blood parasites in Africa over the past 85 years!!

FIGURES 1 - 6 (facing)

1. *Haemoproteus halcyonis* from the Woodland Kingfisher. Arrow points to male which is lighter in colour than the two females to the right in the same picture.
2. *Plasmodium circumflexum* from Swainson's Francolin. All stages of the parasite are illustrated.
3. *Microfilaria* in Greywing Francolin.
4. *Hepatozoon atticorae* from the South African Cliff Swallow.
5. *Trypanosoma calmiettei* from the Cape White-eye.
6. *Leucocytozoon neavei* from the Helmeted Guineafowl.



To highlight this paucity of records from African birds, it is perhaps not surprising to note that only three individual crows (Corvidae) have been examined for haematozoa in Africa over the past 8 decades. Similarly, there are only 15 recorded examinations of the tits (Paridae) for this continent. How many birds of these two families have been handled and/or ringed in the past ten years?

There are a large number of commonly occurring families of birds in South Africa in which no parasites have been recorded. The family Coliidae (mousebirds), for example, has yet to have a single blood parasite recorded from it, presumably because only 26 mousebirds have been examined, although this is one of the more commonly occurring avian families. Species of *Leucocytozoon* have not yet been described from such families as the barbets, kingfishers, starlings and sunbirds, again presumably because of the small sample size.

Recently it has been discovered that the blood parasites of the genus *Hepatozoon* occur more frequently in sub-Saharan birds than anywhere else in the world. Only four species of *Hepatozoon* have been described from birds and absolutely nothing is known about their life cycle or impact on their host. It is speculated that they are transmitted from bird to bird through the agency of soft-shelled ticks, but even this is not clear. The highest prevalence in South African birds of these parasites occur in the puffback shrikes, the helmet shrikes, the tit-babblers and the South African Cliff Swallow. However, hepatozoans have also been recorded in white-eyes, Cape Sparrows and bulbuls. Much more material from these and other birds is required to both describe new species and obtain information on their host range and geographical distribution throughout the continent.

It is possible that the study of blood parasites will assist in clarifying evolutionary relationships among the birds. Gurney's Sugarbird *Promerops gurneyi*, previously classified with the Australian honeyeaters (Melliphagidae) but now placed in the closely related family Promeropidae, is heavily infected in the Lydenburg area with a *Leucocytozoon* species that is identical with *L. anellobiae* of the Australian honeyeaters (Bennett & de Swardt 1989). The presence of this parasite in both continents indicates that the host populations were at one time conspecific but separated at the time of Continental Drift some 40 million years ago. This provides fascinating speculation on the timing of the evolutionary sequences involved.

However, while there are some 200 examinations of Gurney's Sugarbird (thanks to the efforts of Dawie de Swardt of the National Museum) there are only three examinations of the Cape Sugarbird, even though over 400 individuals were ringed in the 1988-89 ringing season alone! Records from this other species would be of great confirmatory value.

This note is a request for ringers to assist us in expanding our data base by taking blood samples from birds, particularly the more infrequently encountered species as well as the more common forms cited previously. Such species might well harbour new species of blood parasites. Additionally, a monthly sample of one easily obtained species, such as the Cape White-eye or Cape Sparrow or a bulbul, taken over one to two years in one locality, would provide valuable information on the fluctuation of the parasite burden and contribute to our understanding of the epizootiology of the parasites involved. This type of information has only been obtained twice in Africa, once in Uganda (Bennett *et al.*, 1974) and once in the northern portions of South Africa (Bennett *et al.*, 1991); in neither case was the study carried out on a single species of bird.

Additional valuable information can be obtained by examining birds from ringing sites in close proximity. In the Pretoria region, for example, some 80 birds representing 16 species at Onderstepoort were heavily parasitized by species of *Leucocytozoon*, but haemoproteids were rarely seen. Three kilometers away near the suburb of Sinoville, a similar sample of the same species showed that species of *Haemoproteus* were the predominant parasites and that leucocytozoids were rare. This showed that the vector (= transmitting) biting fly populations in the geographically closely situated localities were completely different; the Onderstepoort area having an abundance of ornithophilic blackflies while the Sinoville area had an abundance of ceratopogonid biting midges. The parasites also acted as a biological marker for they showed that the two bird populations were relatively sedentary and did not move around to any great extent. Such information is invaluable in studying host-parasite relationships.

Making blood smears from birds is not difficult and the techniques and methodology have been described by Earlé & Grobler in the new SAFRING Bird Ringing Manual that is to appear soon. Ringers interested in collaborating (and we sincerely hope that many ringers will be eager to help us expand our knowledge on the diseases and parasites of wild African birds) should contact Dr. Roy Earlé at the Department of Parasitology, Faculty of Veterinary Science, Onderstepoort 0110. He can advise on the best methodology for obtaining and shipping blood smears and he will ensure that the material is sent to competent authorities for examination and evaluation.

REFERENCES

- BENNETT, G.F., EARLÉ, R.A., DU TOIT, H., CASSIDY, T. and HUCHZERMEYER, F.W. 1991. A host-parasite catalogue of the haematozoa of sub-Saharan birds. Onderstepoort Journal of Veterinary Research (in press).

BENNETT, G.F. & DE SWARDT, D.H. 1981. First African record of *Leucocytozoon anellobiae* (Apicomplexa: Leucocytozoidae) in Gurney's Sugarbird, *Promerops gurneyi*. Ostrich 60: 171.

BENNETT, G.F., OKIA, N.O. & CAMERON, M.F. 1974. Avian haematozoa of some Ugandan birds. Journal of Wildlife Diseases 10: 458-465.

GREINER, E.C., BENNETT, G.F., WHITE, E.M. & COOMBS, R.F. 1975. Distribution of the avian haematozoa of North America. Canadian Journal of Zoology 53: 1762-1787.

McCLURE, H.E., POONSWAD, P., GREINER, E.C. & LAIRD, M. 1978. 'Haematozoa in birds of eastern and southern Asia'. International Reference Centre for Avian Haematozoa: Memorial University of Newfoundland Press, 296 pp.

OATLEY, T.B. 1990. Safring statistics for the 1988-89 ringing year. Safring News 19: 27-34.

WHITE, M., GREINER, E.C., BENNETT, G.F. and HERMAN, C.M. 1978. Distribution of the haematozoa of Neotropical birds. Revista Biologica Tropica 26: 43-102.

WOODWORTH-LYNAS, C.B., CAINES, J.R. and BENNETT, G.F. 1989. Prevalence of avian haematozoa in Sao Paulo State, Brazil. Memorias do Instituto Oswaldo Cruz (Rio de Janeiro) 84: 515-526.

Roy A. Earlé, Faculty of Veterinary Science, University of Pretoria 0110, Onderstepoort, REPUBLIC OF SOUTH AFRICA.

Gordon F. Bennet, Department of Parasitology, Faculty of Veterinary Science, University of Pretoria, 0110 Onderstepoort, Republic of South Africa and International Reference Centre for Avian Haematozoa, Memorial University of Newfoundland, St. John's, Newfoundland, CANADA, A1B 3X9.